Late pacemaker perforation of the right ventricle. A case report and review of diagnosis and management

Vivian Shokry, Ehab Gamil Daoud

Abstract

***Objectives*: Pacemaker incidence and prevalence are on the rise over the last decade especially in the elderly population. Though complications are rare, most reported literature is about early pacemaker complication. Late complications are also reported, but mostly regarding malfunction or infections. Very few case reports and series report late cardiac perforations which could be catastrophic. We report a case of late cardiac perforation diagnosed and treated in our institution to raise the awareness of this very serious complication.**

***Case summary*: A 65-year-old male who had a single chamber right ventricular pacemaker inserted two months earlier for sick sinus syndrome, presented to the hospital with complaint of shortness of breath. Chest X-ray (CXR) revealed new large left sided pleural effusions. Computed tomography (CT) scan of the chest suggested migration of the pacemaker lead with perforation of the right ventricle associated with hemothorax with no pericardial effusions. A bedside echo confirmed the perforation and showed minimal pericardial effusions with no cardiac tamponade. Clinically patient was hemodynamically stable. He underwent open surgical repair and placement of epicardial pacer leads.**

***Conclusions*: Clinicians should be aware of the early and late complications of pacemaker insertions and how to diagnose and treat them appropriately to avoid unnecessary morbidity or mortality.**

Key words: Cardiac perforation, hemothorax, cardiac tamponade.

Case summary

A 65-year-old male who had a single chamber right ventricular pacemaker inserted two months earlier for sick sinus syndrome, presented to the hospital with complaint of shortness of breath. Chest X-ray (CXR) revealed new large left sided pleural effusions. Computed tomography (CT) scan of the chest suggested migration of the pacemaker lead with perforation of the right ventricle (**Figure 1**) associated with hemothorax with no pericardial effusions. A bedside echo confirmed the perforation and showed minimal pericardial effusions with no cardiac tamponade. Clinically patient was hemodynamically stable. He underwent open surgical repair and placement of epicardial pacer leads (**Figure 2**).

Clinicians should be aware of the early and late complications of pacemaker insertions to avoid unnecessary morbidity or mortality.

From Kuakini Health System, Honolulu, USA (Vivian Shokry), University of Hawaii, John Burns School of Medicine, Kuakini Health System, Honolulu, USA (Ehab Gamil Daoud).

Address for correspondence:
Ehab Gamil Daoud, MD, FACP, FCCP
Assistant Professor, University of Hawaii, John Burns School of Medicine
Kuakini Health System
347 N Kuakini St, Honolulu, HI 96817, USA
Tel: 1 (440) 655-9697
Email: ehab_daoud@hotmail.com

Discussion

Cardiac pacemakers are a proven therapy for cardiac conduction disturbances and many arrhythmias. Despite their lifesaving benefits, they are associated with number of complications that can be fatal. (1) Complications can be subdivided into acute, subacute, chronic, or early (within first months), and late (after first month). (2) **Table 1** summarizes the potential complications of pacemakers.

Pacemaker associated myocardial perforations are rare with reported overall lead perforation rates after pacemaker implantation to be 0.1-0.8%. (3) Majority of those cases occur early within 24 hours after implantation, late cases are even rarer. (4)
Symptoms can include chest pain, shortness of breath, syncope, abdominal pain, hiccups, but sometimes asymptomatic. (5) Hemothorax, pneumothorax, or cardiac tamponade are rare. Pacemaker malfunction can be the only reported indication of perforation. (1,5) Risk factors for perforation are summarized in **Table 2**. (1,5)
CXR, CT scan, or echocardiogram can confirm the diagnosis. CT is considered the gold standard in diagnosis. (1,6)
Management depends mainly on the patient's clinical condition. Guidelines for management were published by the Heart Rhythm Society (HRS) in 2009, and recently updated in 2017. Most experts recommend whole device and lead extraction. Percutaneous extraction, versus open surgical extraction, and repair are valid options. The procedure should occur in a centre specializing in percutaneous lead extraction either direct traction or percutaneous lead extraction in the operating room, in presence of cardiosurgical, anaesthesiological and echocardiographic teams. (7-10)

Table 1. Common early and late complications of pacemaker insertion

Early	Late
Pneumothorax	Venous thromboembolism
Hemothorax	Infection
Air embolism	Twiddler syndrome
Cardiac perforation and tamponade	Cardiac perforation and tamponade
Coronary sinus dissection	Pacemaker syndrome
Pocket hematoma	Pacemaker-mediated arrhythmias
Lead dislodgment	Runaway pacemaker
Infection (pocket, sepsis)	Lead failure
Loose set screws	Pacemaker malfunction
Diaphragmatic stimulation	Electromagnetic interference

Table 2. Risk factors for pacemaker perforation

Lead property - Temporary stimulation - Atrial leads - Active fixation
Cardiac muscle - Dilated cardiomyopathy
Patient characteristics - Elderly - Female gender - Low body mass index
Medications - Anticoagulation - Steroids
Chest trauma

Figure 1. CT scan of the chest showing migration of the pacemaker lead out of the right ventricle towards the chest wall associated with large right sided hemothorax

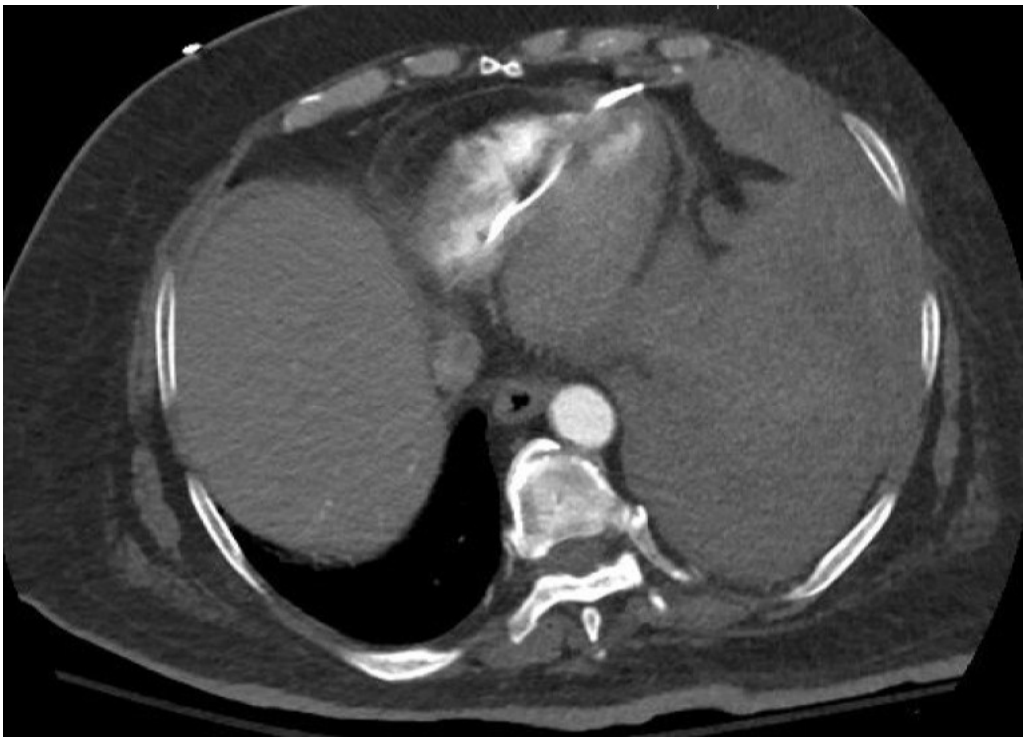

Legend: CT=computed tomography.

Figure 2. Picture of the pacemaker lead perforating the right ventricle apex during surgical extraction and repair

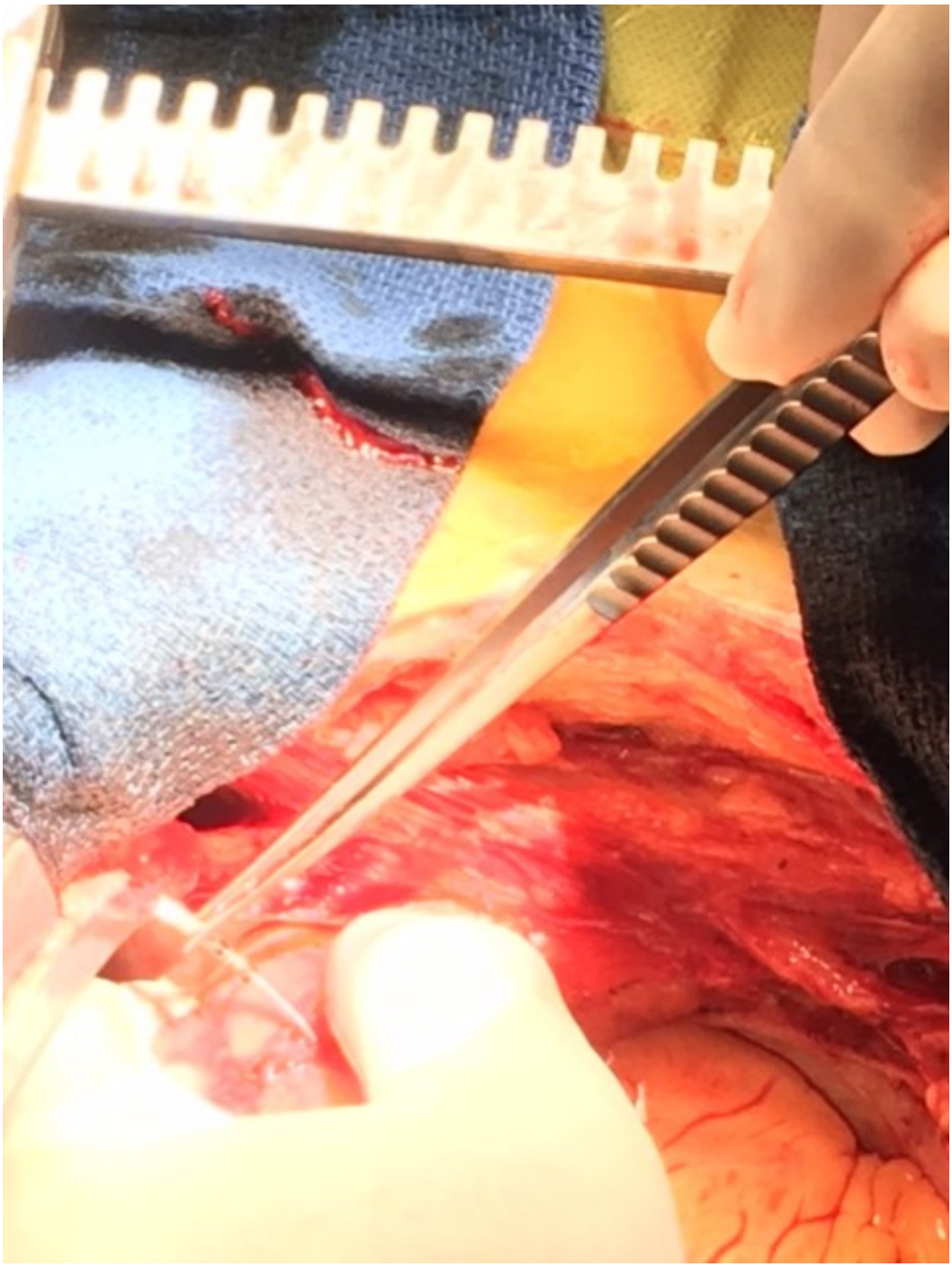

References

1. Banaszewski M, Stępińska J. Right heart perforation by pacemaker leads. Arch Med Sci 2012;8:11-3.
2. Upadhyay GA, Singh JP. Pacemakers and defibrillators. In: Fuster V, Harrington RA, Narula J, Eapen ZJ, editors. Hurst's The Heart. 14th ed. New York (NY): McGraw-Hill; 2017.
3. Piekarz J, Lelakowski J, Rydlewska A, Majewski J. Heart perforation in patients with permanent cardiac pacing - pilot personal observations. Arch Med Sci 2012;8:70-4.
4. Tziakas D, Alexoudis A, Konstantinou F, Chalikias G, Stakos D, Bougioukas G. A rare case of late right ventricular perforation by a passive-fixation permanent pacemaker lead. Europace 2009;11:968-9.
5. Rydlewska A, Małecka B, Ząbek A, Klimeczek P, Lelakowski J, Pasowicz M, et al. Delayed perforation of the right ventricle as a complication of permanent cardiac pacing - is following the guidelines always the right choice? Non-standard treatment - a case report and literature review. Kardiol Pol 2010;68: 357-61.
6. Henrikson CA, Leng CT, Yuh DD, Brinker JA. Computed tomography to assess possible cardiac lead perforation. Pacing Clin Electrophysiol 2006;29:509-11.
7. Byrd CL. Managing device-related complications and transvenous lead extraction. In: Ellenbogen KA, Kay GN, Lau CP, Wilkoff BL, editors. Clinical cardiac pacing, defibrillation, and resynchronization therapy. 3rd ed. Fhiladelphia: W.B. Saunders and Elsevier Company; 2007. P. 855-966.
8. Kutarski A, Opolski G. PM/ICD lead extraction - most difficult and potentially hazardous electrotherapy procedure - logistic and training problems. Kardiol Pol 2010;68:736-42.
9. Wilkoff BL, Love CJ, Byrd CL, Bongiorni MG, Carrillo RG, Crossley GH 3rd, et al. Transvenous lead extraction: Heart Rhythm Society expert consensus on facilities, training, indications, and patient management: This document was endorsed by the American Heart Association (AHA). Heart Rhythm 2009;6:1085-104.
10. Kusumoto FM, Schoenfeld MH, Wilkoff BL, Berul CI, Birgersdotter-Green UM, Carrillo R, et al. 2017 HRS expert consensus statement on cardiovascular implantable electronic device lead management and extraction. Heart Rhythm 2017;14:e503-51.